



Omental Infarction: About A Case

Infarto del omento mayor: a propósito de un caso



Alejandro Zuluaga Santamaría¹
Valentina Grand Vallejo²
Rafael Llamas Otero³
Ricardo Uribe González³



Key words (MeSH)

Mesentery
Mesenteric ischemia
Abdominal pain
Tomography, X-Ray
computed



Palabras clave (DeCS)

Mesenterio
Isquemia mesentérica
Dolor abdominal
Tomografía computarizada
por rayos x

Summary

Omental infarction is a rare disease that occurs as a cause of abdominal pain. It requires an adequate diagnosis based on the image characteristics, since its recognition guides the management that in the majority of the cases is conservative. However, surgical management may be necessary in some cases. Among the imaging modalities used for the study of abdominal pain, multidetector computed tomography (MCT) is the most accurate imaging modality for the diagnosis of omental infarction. We present a case of a patient with torsion and infarct of the mayor omentum in the right side that required surgery. We make a literature review of omental infarction, emphasizing in the imaging findings, the most common differential diagnosis and treatment of the pathology.

Resumen

El infarto del omento es una enfermedad poco frecuente que se manifiesta como causa de dolor abdominal. Se requiere un diagnóstico adecuado, basado en las características por imagen, puesto que su reconocimiento orienta el manejo que en la mayoría de los casos es conservador. Sin embargo, en algunos casos puede ser necesario el manejo quirúrgico. Dentro de las modalidades de imagen utilizadas para el estudio del dolor abdominal agudo, la tomografía computarizada multidetector (TCM) es la modalidad de imagen con mayor precisión para realizar diagnóstico de infarto del omento. Se presenta el caso de un paciente con torsión e infarto del omento mayor en el lado derecho, que requirió cirugía. Se realiza una revisión de la literatura sobre el infarto del omento mayor enfatizando los hallazgos por imágenes, los diagnósticos diferenciales más frecuentes y el tratamiento de esta entidad.

1. Case

A 23-year-old male patient who does not present a relevant personal history. Consultation with the emergency department for a clinical picture of 6 hours of evolution, consisting of pain in the right iliac fossa associated with subjective fever and vomiting. He had previously presented on several occasions a similar clinical picture of abdominal pain, of lesser intensity, controlled with medical management.

Upon physical examination, he was found to have tachycardia, febrile, with pain on palpation of the right iliac fossa (RIF) and abdominal defense. Laboratory tests show a slightly increased PCR of 3.6 mg / dl and normal leukocytes of 8,300. Within the initial diagnoses, urolithiasis is suspected, for which a UROTAC is performed with an increase in

fat density in the right iliac fossa, in the topography of the greater omentum, without free fluid, or pneumoperitoneum (Figure 1).

The diagnosis of infarction of the greater omentum is suggested. In the general surgery department they suspect an acute appendicitis, so they perform a multidetector computed tomography (MCT) of the abdomen with contrast medium (Figure 2).

In the MCT, an increase in the density of the fat is identified in the topography of the greater omentum, in the right flank and the ipsilateral iliac fossa, with vascular engorgement and “swirling” effect of the vascular structures of the greater omentum. The cecal appendix is partially visualized without inflammatory signs. These findings are suggestive of torsion of the greater omentum with associated infarction.

¹Radiologist, Cedimed and Medimagen. Professor of Radiology, Universidad CES and UPB, Medellín, Colombia.

²Radiology resident of the Universidad UPB and Cedimed, Medellín, Colombia.

³Radiology resident of the Universidad CES, Medellín, Colombia.

The patient undergoes a surgery in which rotation of the omentum with signs of necrosis is found, which is why it is resected. It is confirmed that the cecal appendix does not have inflammatory signs (Figure 3).

The patient evolves satisfactorily and is discharged four days after surgery.

2. Introduction

Fat necrosis is a frequent finding in abdominal images. It can cause abdominal pain and manifest itself clinically imitating a picture of acute abdomen, or it can be asymptomatic and accompany other physiopathological processes.

Common processes that are indicative of fat necrosis include: infarction of the greater omentum, torsion of an epiploic appendix and fat necrosis related to trauma or pancreatitis. Other less common pathologies include hypertrophy or atrophy of fat and malignant processes, such as liposarcoma and carcinomatosis, which can mimic benign causes of fat striation (1).

Omental infarction is a rare cause of acute abdominal pain (2-4) due to vascular compromise (3,4) and was described for the first time more than 100 years ago (5). It has an incidence of 0,0016% to 0.37% (4,6,7) and is equivalent to less than 4 per 1,000 cases of appendicitis, cholecystitis, pancreatitis and other abdominal pathologies (4,8). The increasing use of high quality images in the study of acute abdomen, such as the CT scan of the abdomen, has made it possible to perform the diagnosis of omental infarction more frequently (9).

Onset infarction usually occurs on the right side. This location is related to the greater length and mobility that makes it more prone to twist on itself along its long axis and to compromise vascularization (1,3). However, omental infarction has also been described on the left side (3).

The most common age of appearance is between the fourth and fifth decades of life (3, 5), but there are cases of children from 28 months of age (6). It is prevalent in men (4) with a ratio of 4: 1 with respect to women (6).

The differential diagnosis should be made with appendicitis, inflammation of the epiploic appendix, acute diverticulitis, colitis, pancreatitis, duodenal ulcer, mesenteric panniculitis, among others (3,10).

3. Anatomy

Fat is present both in the intraperitoneal compartment and in the retroperitoneal compartment.

The main structures that contain fat in the intraperitoneal compartment are the greater omentum and the mesentery. Therefore, it is important to establish the precise location of the pathological condition to make an adequate diagnosis and rule out other differential diagnoses (1).

The omentum is an embryological remnant. It is divided into major and minor (8). The greater omentum is composed of a double layer of peritoneum that extends inferiorly from the greater curvature of the stomach, bends over itself upwards and covers the trans-

verse colon extending to the pancreas.

It is a mobile structure and its function is to contain the spread of infections and tumors, which is why it is known as “the abdomen policeman” (1,9).

Its irrigation is carried out through the right and left gastropiploic arteries (11). It contains glasses and fat (1,3).

In the MCT, the greater healthy omentum is seen as a band of fat with vessels, located just anterior to the transverse colon and has a variable anteroposterior diameter that depends on the weight of the patient (11).

The mesentery of the small intestine is a fold of visceral peritoneum that is fixed from the intestine to the posterior abdominal wall. It contains fat and superior and inferior mesenteric vessels with their branches.

The vascular reference points provide a means of identifying their different segments. For example, the meso transverse colon connects the intraperitoneal transverse colon with the posterior abdominal wall and contains the middle colic branch of the superior mesenteric artery; the sigmoid mesocolon fixes the sigmoid to the posterior pelvic wall and contains the branches of the inferior mesenteric vessels (1).

4. Etiology

Leitner proposed that the omentum infarction can be divided into primary or idiopathic and secondary (2,3,8). And although primary torsion was described since 1899 by Eitel (4), it is rare due to its abundant collateral vessels. However, the lateral border on the right side of the omentum has a blood supply that is fainter than the rest of the omentum; which raises the hypothesis that this tenuous blood supply makes it more vulnerable to heart attack.

4.1 Primary infarct of the omentum

It is unipolar and manifests when a mobile segment of the omentum rotates over a fixed proximal point, without there being another intra-abdominal pathology (3), which is the main cause of infarction (12).

The risk factors for this condition are: trauma, obesity, ischemia, venous kinking with cough or physical activity, hypercoagulable states, increased peristalsis, anatomical variants (3,8), such as the bifid or accessory omentum (4), the redundant omentous veins (9,10,12-14) and the use of laxatives (8).

Congestion of the mesenteric vein due to systemic diseases, such as right heart failure, vasculitis and pancreatitis (1,9,13), is a described cause of infarction, which appears more frequently in the pediatric age (14).

A hemorrhagic infarct resulting from vascular compromise can often occur due to decreased blood supply to the right side of the omentum and torsion of the veins (9,10,12,13).

4.2 Secondary infarct of the omentum

It is bipolar with two fixed ends between which the omentum torsion occurs. It is the most common and occurs secondary to trauma, surgery or other abdominal pathology (3), such as cysts, tumors, intra-abdominal inflammation, hernias (3,4,8) and vasculitis (8).

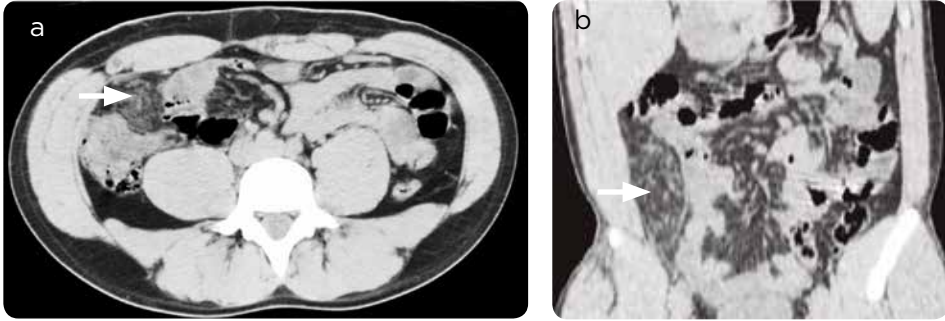

Figure 1. Simple multi-slice computed tomography of the abdomen (UROTAC). a) Axial section: increase in fat density in the topography of the greater omentum in the right iliac fossa (arrow) without free fluid or pneumoperitoneum. The cecal appendix is not properly identified. There is no hydronephrosis, nor ureteral stones that explain the cause of the pain. b) Multiplanar reconstruction, coronal cut. The location of the finding observed in the axial section is confirmed (arrow).

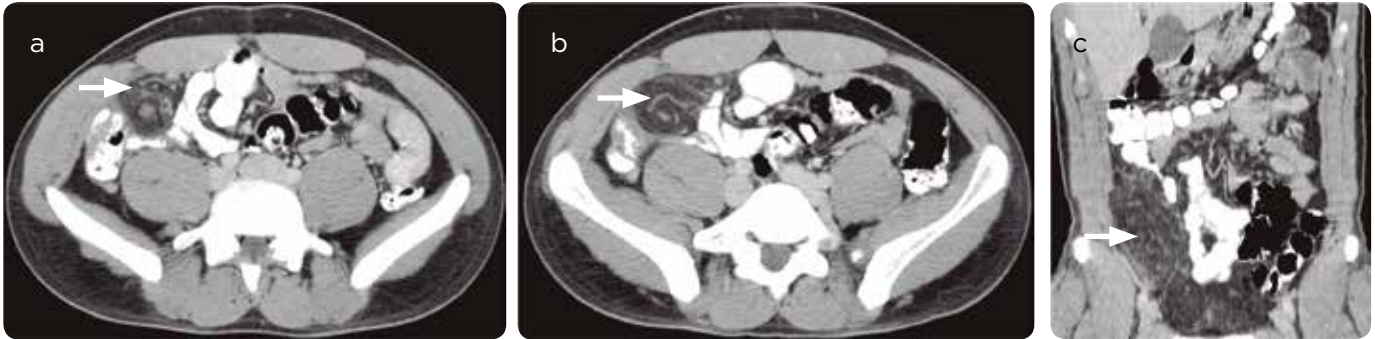

Figure 2. MCT of abdomen with contrast medium (oral positive and intravenous). a and b) Axial cuts, c) coronal cut. A pseudonodular lesion with increased fat density is identified in the topography of the greater omentum, both in the iliac fossa and in the flank, both rights, which exerted mass effect on the cecum, ascending colon and terminal ileum. The lesion measures 3.1 × 6.5 × 10.6 cm (AP × T × L). There is vascular engorgement and “whirlpool” effect of the vascular structures of the greater omentum. Finding suggestive of twisting and infarction of the omentum (arrows).

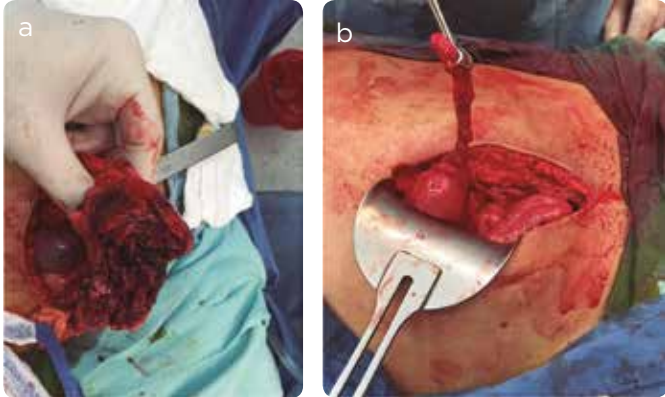


Figure 3. Surgical images. a) Exposure of the omentum with signs of ischemia and necrosis. Finding that correlates with the UROTAC images and the MCT of the abdomen with contrast medium. b) Healthy cecal appendix.

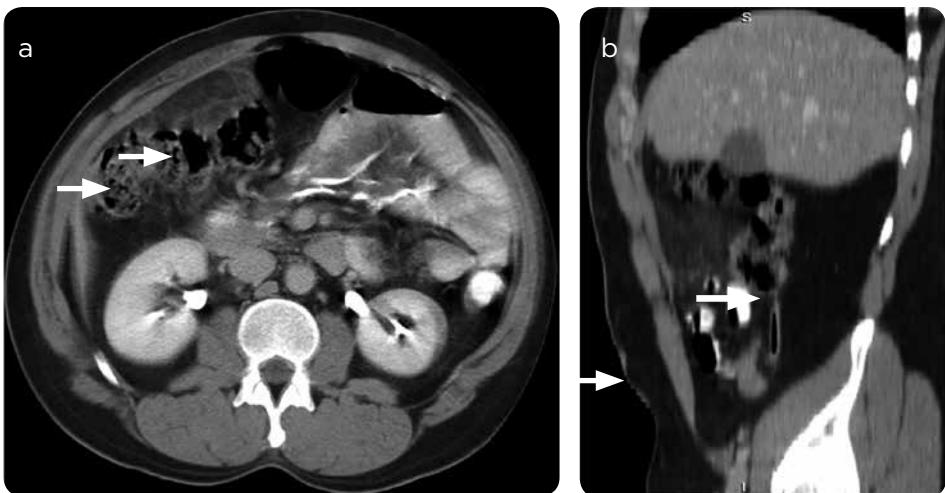


Figure 4. MCT of abdomen with contrast medium. a) Axial cut. omentum infarction (arrows). b) Coronal cut. Normal cecal appendix (arrows).

5. Clinical

Patients consult for sudden onset abdominal pain that increases in intensity (3,4,7), but does not radiate to the abdominal wall (4). Occasionally, it may be accompanied by nausea, vomiting, anorexia, fever, gastrointestinal tract dysfunction (3,5,7) and accompanied by elevation of acute phase reactants (3,5).

Upon physical examination some patients may manifest symptoms of peritoneal irritation (4).

6. Imaging findings

6.1 MCT

In infarction, an area with high attenuation fat density centered on the omentum (1,3,7,8,11) is seen with a high density ring (15) that can be close to the colon (3,11). It may be accompanied by reactive thickening of the GIT wall, but this will be less than the striation of the fat (3,11). When the omentum infarction is secondary to torsion, concentric linear images or “whirlwind” signs are seen (1,2,5,7,8,13) (Figure 4).

Rarely, the omentum infarction compromises the left side (Figure 5).

6.2 Ultrasound

The typical finding is a hyperechoic mass (4,5,7) that is not compressed (4,7) and is attached to the abdominal wall (4).

7. Differential diagnoses

7.1 Appendicitis

The appendix is a blind tubular structure (16) that represents a true diverticulum located at the base of the cecum near the ileocecal valve (7).

Under normal conditions it measures between 6 and 9 cm in length (7), has a maximum transverse diameter of 6 mm (11) and a normal thickening of its wall of less than 2 mm (16).

The pathogenesis begins with the luminal obstruction caused by lymphoid hyperplasia, fecalites, foreign bodies, viral infections, pyogenic, parasitic and in a lesser proportion may have a neoplastic origin. Subsequently, the continuous secretion of intraluminal mucus causes an elevation of the pressure with distension, venous congestion, arterial compromise and tissue ischemia (11,17).

The luminal bacteria multiply and invade the appendicular wall, which causes transmural inflammation, produces appendicular infarction and microperforation. At this point, the inflammation extends to the parietal peritoneum and adjacent structures (11).

The diagnosis of acute appendicitis is made based on the clinical history, laboratory tests and essentially with the physical examination (7). However, about 20-33% of patients with possible appendicitis present atypical features (17). The physical examination has a general diagnostic accuracy that ranges between 78 and 92% in male patients and is much lower in the female sex with a range between 58 and 85% (7). Additionally, the pelvic or retro-ileal position and retrocecal position of the appendix can make diagnosis difficult, because the abdominal

pain can be located in the pelvis or in the right flank and costovertebral angle, respectively, unlike the pain located in the iliac fossa right that is observed in the classic picture of acute appendicitis (7).

The MCT is a test with excellent accuracy for the diagnosis of acute appendicitis with a sensitivity and specificity of 94% and 95%, respectively, in adults and adolescents (17-19) and 94% and 95% respectively in children (11). This method offers results superior to those of ultrasound, which has a sensitivity of 86% and specificity of 81% (18).

Magnetic resonance imaging (MRI), in turn, presents an excellent sensitivity and specificity for the diagnosis of acute appendicitis from 97 to 100% and from 92 to 93.6%, respectively (16).

According to the adequacy criteria of the American College of Radiology (ACR), the use of MRI is more appropriate than the use of the MCT in pregnant patients with right lower quadrant pain, fever and leukocytosis. It is also an attractive alternative, after ultrasound, for this group of patients and for the pediatric population, in whom exposure to ionizing radiation is a major concern. It is considered, therefore, as the second imaging modality after ultrasound in these two groups of patients when the ultrasound results are not diagnostic or equivocal (16).

The findings of acute appendicitis in MCT reflect the severity of the inflammation (7). Thus, the air or contrast material in the appendix, surrounded by normal-looking fat, indicates absence of appendicitis.

In mild cases, the findings are subtle and you can see a minimally distended appendix, filled with fluid, with a normal diameter and without striation of the adjacent fat. Direct luminal distension between 7 to 15 mm of transverse diameter, with an abnormal circumferential thickening of the wall greater than 2 mm (16), an enhancement of the appendicular wall have been described as direct signs of acute appendicitis (11). After administration of the contrast medium, which can be homogeneous or stratified (finding known as the “target” sign) (7) and spiculated or filamentous aspect striation of the pericecal and peripendicular fat (7,16) (Figure 6).

Indirect or secondary signs of acute appendicitis are: an appendicolith (not always indicates appendicitis and may be an incidental finding) (7), the thickening of the cecal apex that can be identified by two signs: 1. Sign of the cecal bar, which represents the linear inflammatory change that separates the base of the appendix from the contrast-filled caecum or an appendicolith. 2. “Arrowhead” sign that is formed by the triangular thickening of the cecum that surrounds the appendicular orifice (7,17).

To achieve an adequate identification of the cecal appendix and the signs described above, it is important to achieve optimal opacification and distention of the cecum with contrast material, which can be administered orally and / or through the rectum. However, no technique shows a statistically significant difference in diagnostic accuracy.

Other periappendicular inflammatory signs include phlegmon, fluid, bubbles, abscess and lymphadenopathy (7).

7.2 Mesenteric adenitis

Inflammation of the mesenteric lymph nodes that can generate acute or chronic abdominal pain (7), with nonspecific clinical presentation (7). It is the second most common cause of abdominal pain in the right lower quadrant after appendicitis (7).

Mesenteric adenitis is primarily an imaging diagnosis and is divided into two groups: Primary and secondary (6).

- » Primary: Conglomerate of 3 or more adenopathies in the right lower quadrant that measure 5 mm or more, without apparent inflammatory event or with slight thickening of the terminal ileum (<5 mm) (7). Infectious ileitis has been postulated as its most common cause (7) (figure 7).
- » Secondary: It is associated with other etiologies such as appendicitis, Crohn's disease, colitis, lupus, among others (7).

7.3 Diverticulitis

It is one of the most common causes of pain in the left abdomen (3). The inflamed diverticulum is seen with striation of the fat, thickening and enhancement of the wall of the adjacent colon (3) (Figure 8). The complications are fistulas, abscesses and perforation (3).

7.4 Inflammation of epiploic appendix

It is a benign and self-limited pathology that causes abdominal pain. It is produced by inflammation, torsion or ischemia of the epiploic appendages (3,7), which are small benign evaginations of the antimesenteric portion of the colon (in its serous layer) to the fat of the visceral peritoneum and contain blood vessels (3).

The epiploic appendages are found in any portion of the colon, but most appear in the sigmoid (48% of cases). The second most frequent location is the descending colon, followed by the ascending colon (7).

The findings in MCT include: Increase in fat density adjacent to the antimesenteric portion of the colon, with an ovoid shape and with a peripheral ring that enhances (3,7). You can also see a punctate, high-density, centrally located image representing a blood vessel. These findings are associated with a thickening of the colon wall (7, 11) (Figure 9).

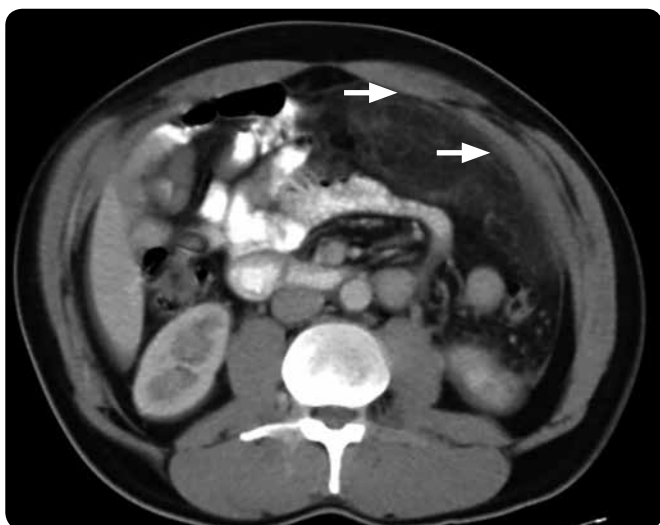

Figure 5. Omentum infarction on the left side (arrows).

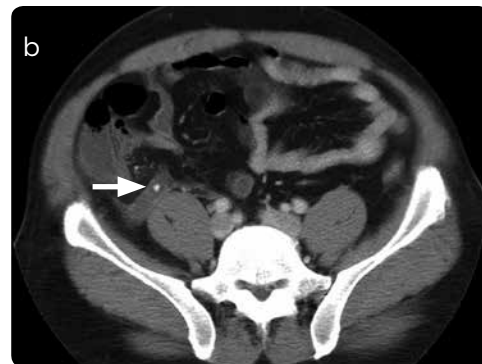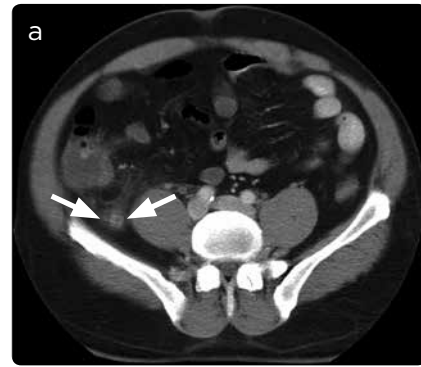


Figure 6. a) Inflamed appendix with increased transverse diameter, thickening and contrast enhancement of the wall, and increased density of the surrounding fat (arrows). b) Appendicolite (arrow).

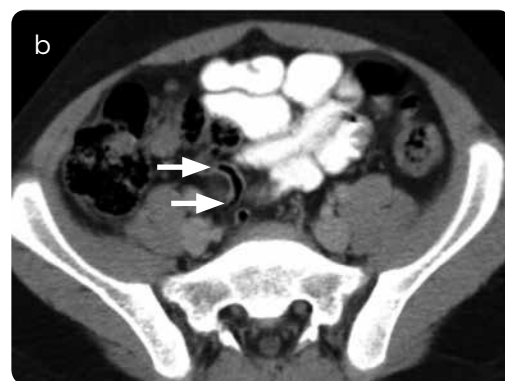
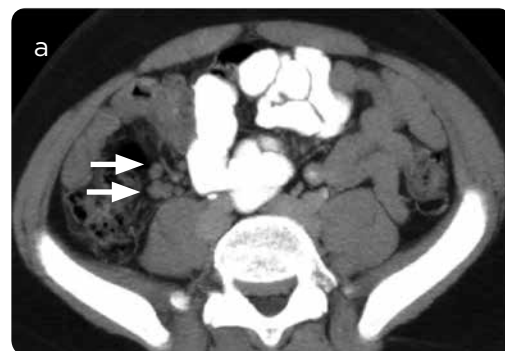
Figure 7. Patient of 15 years with pain in the right iliac fossa. a) Multiple mesenteric lymph nodes forming a conglomerate (arrows). b) Normal cecal appendix (arrows).

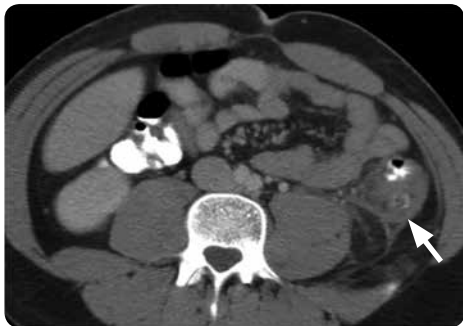

Figure 8. Posterior diverticulum of the descending colon with thickened walls (arrow), increased pericolic fat density, thickening of the lateroconal fascia, pericolic fluid and thickening of the posterior wall of the colon.

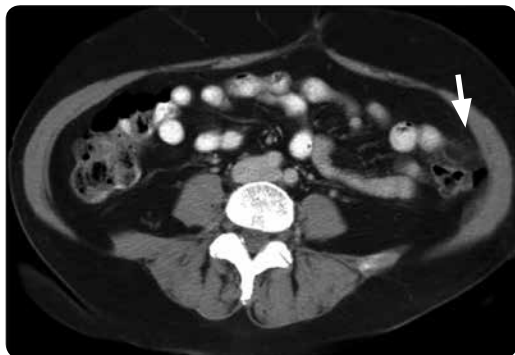


Figure 9. Oval image at the antimesenteric border of the colon, with increased density and striation of the adjacent fat. In addition, ring peripheral enhancement (arrows).

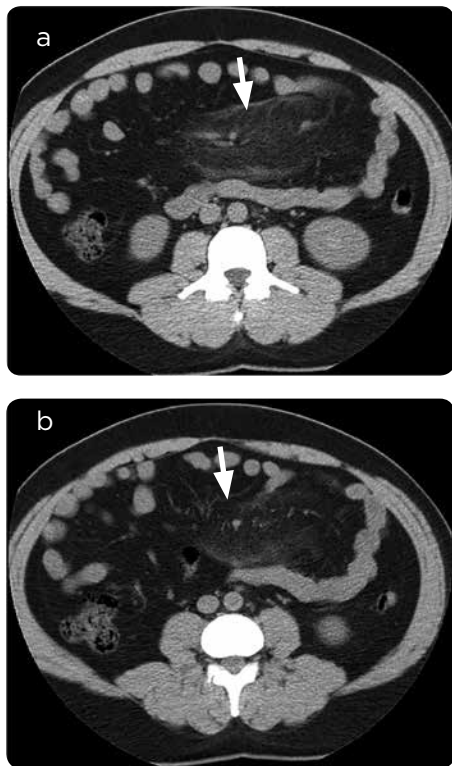


Figure 10. a) Increase in the density of the fat in the root of the mesentery, with anterior pseudocapsule. b) Respect for the density of perivascular fat (arrows).

When the inflammatory process is resolved, usually the findings described above disappear completely in the images. However, sometimes, as part of the healing process, the epiploic appendix can calcify and separate from the wall of the colon, moving freely through the peritoneal cavity (7).

7.5 Mesenteric panniculitis

It is a disease of unclear cause. It can be presented as a single manifestation or be associated with several clinical conditions.

These patients consult for progressive or intermittent abdominal pain with a palpable abdominal mass (3). In the MCT, an increase in the density of the fat located in the root of the mesentery is identified, respecting the normal density of the fat of the periphery of the vessels. Also, a pseudocapsule of mainly anterior location and small adjacent lymph nodes smaller than 1 cm (3) are observed (Figure 10).

Conservative management for this disease is recommended with anti-inflammatories, analgesics and antibiotics (4,8,15), although it has been described as a self-limiting condition (11,15). Surgical management is reserved for cases in which the diagnosis is doubtful and is associated with signs of peritoneal irritation, uncontrollable pain (15), infection or signs of intestinal obstruction. Follow-up by imaging is done to rule out the development of other entities that may initially have similar manifestations, such as carcinoid tumor or lymphoproliferative disorders (12).

8. Conclusion

Infarction of the major omentum is a rare cause of acute abdominal pain. It is a diagnosis of exclusion and other entities that alter the density of intraperitoneal fat should be ruled out beforehand. Generally it compromises the right side and is of conservative management.

A case of omental infarction with unusual evolution was presented, which required surgical management and showed torsion of the greater omentum, both in the images and in surgery.

References

1. Kamaya A, Federle MP, Desser TS. Imaging manifestations of abdominal fat necrosis and its mimics. *Radiographics*. 2011;31(7):2021-34.
2. Eunhye Y, Hee KJ, Kim M-J. Greater and lesser omenta: Normal anatomy and pathologic processes I. *Radiographics*. 2007;707-21.
3. Tonerini M, Calcagni F, Lorenzi S, Scalise P, Grigolini A, Bemì P. Omental infarction and its mimics: imaging features of acute abdominal conditions presenting with fat stranding greater than the degree of bowel wall thickening. *Emerg Radiol*. 2015;431-6.
4. Occhionorelli S, Zese M, Cappellari L, Stano R, Vázquez G. Acute abdomen due to primary omental torsion and infarction. *Case Rep Surg*. 2014;2014:1-4.
5. Soobrah R, Badran M, Smith SG. Conservative management of segmental infarction of the greater omentum: a case report and review of literature. *Case Rep Med*. 2010;2010:10-2.
6. Rao A, Remer EM, Phelan M, Hatem SF. Segmental omental infarction. *Emerg Radiol*. 2007;14(3):195-7.
7. Patel NB, Wenzke DR. Evaluating the Patient with right lower quadrant pain. *Radiol Clin North Am*. 2015;53(6):1159-70.
8. Barai KP, Knight BC. Diagnosis and management of idiopathic omental infarction: A case report. *Int J Surg Case Rep*. 2011;2(6):138-40.
9. Itenberg E, Mariadason J, Khersonsky J, Wallack M. Modern management of omental torsion and omental infarction: A surgeon's perspective. *J Surg Educ*. 2010;67(1):44-7.

10. Paroz A, Halkic N, Pezzetta E, Martinet O. Idiopathic segmental infarction of the greater omentum: A rare cause of acute abdomen. *J Gastrointest Surg.* 2003;7(6):805-8.
11. Pereira JM, Sirlin CB, Pinto PS, Jeffrey RB, Stella DL, Casola G. Disproportionate fat stranding: a helpful CT sign in patients with acute abdominal pain. *Radiographics.* 2004;24(3):703-15.
12. Abdulaziz A, Zalabany T El, Rahim A, Sayed A, Ansari A Al. Case Report idiopathic omental infarction , diagnosed and managed laparoscopically: A case report. *Case Rep Surg.* 2013;2013:3-6.
13. Park TU, Oh JH, Chang IT, Lee SJ, Kim SE, Kim CW, et al. Omental infarction: Case series and review of the literature. *J Emerg Med.* 2012;42(2):149-54.
14. García Garrigos E, Pascual Robles MD. Torsión omental secundaria a hernia inguinal. *Radiología.* 2015;57(2):173-4.
15. Litzau M, Lall MD. Idiopathic left upper quadrant omental infarction: Diagnosed and managed conservatively in the ED. *Am J Emerg Med.* 2015;33(5):741.e1-741.e2.
16. Singh A, Danrad R, Hahn PF, Blake MA. MR imaging of the acute abdomen and pelvis: Acute appendicitis and beyond. *Radiographics.* 2007;27(5):1419-31.
17. Ostiz M, Amorena E, Campillo A, Bermejo R, Escolar F. Apendicitis aguda atípica diagnosticada durante una colonoscopia. *An Sist Sanit Navar.* 2013;36(1):129-31.
18. Reich B, Zalut T, Weiner SG. An international evaluation of ultrasound vs. computed tomography in the diagnosis of appendicitis. *Int J Emerg Med.* 2011;4(1):68.
19. Van Randen A, Laméris W, Van Es HW, Van Heesewijk HPM, Van Ramshorst B, Ten Hove W, et al. A comparison of the accuracy of ultrasound and computed tomography in common diagnoses causing acute abdominal pain. *Eur Radiol.* 2011;21(7):1535-45.

Correspondence

Ricardo Uribe González
 Diagonal 29D # 9A Sur-150
 Medellín, Colombia
 ricardouribegonzalez@gmail.com

Received for evaluation: January 30, 2017

Accepted for publication: November 23, 2017